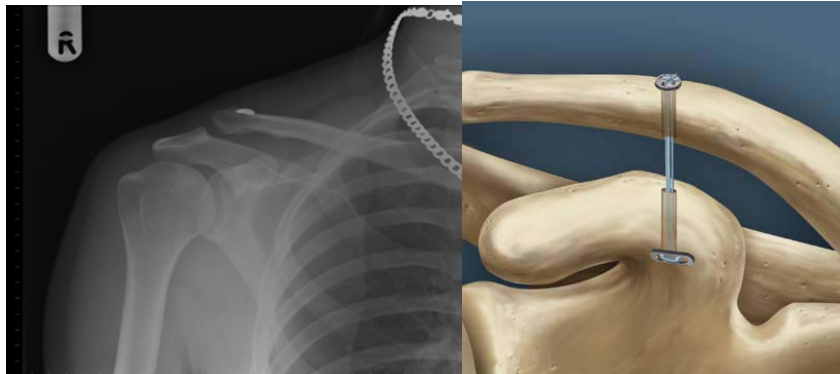


ACJ TIGHTROPE FIXATION



Patient to be seen within 2 weeks of discharge from the Orthopaedic Unit at Macclesfield District General Hospital

OPERATION

Purpose

A simple, minimally invasive technique for acute acromioclavicular joint stabilisation. If the joint is reduced acutely and held reduced during the healing phase, the native ligaments will heal restoring the stability of the joint.

Case profile

This technique is indicated for acute acromioclavicular joint dislocation (Rockwood type III to VI) of less than one month duration.

Main possible complications

Acromioclavicular joint subluxation.

THERAPIST

In patient

- Patient to remain in polysling for 6 weeks.
- Only to remove sling for washing and elbow exercises for 2 weeks.
- No active shoulder movements until 2 weeks
- Can commence elbow flexion/ extension with upper limb supported.
- Upper limb **NOT** to hang down, unsupported for **6 weeks**.

2 weeks

- Can commence **supported** shoulder external rotation.

4 weeks

- Can commence **supported** shoulder flexion and abduction.

6 weeks

- Can wean off polysling and commence full active range of movement at shoulder.
- Avoid heavy resistance work for 3 months.